

REVIEW

Prosthetically driven Implant Placement. How to achieve the appropriate implant site development

Federico Brugnamì and Cristiano Caleffi

Private Practice, Rome, Italy

(Received for publication on March 23, 2005)

(Revised for publication on June 27, 2005)

(Accepted for publication on August 24, 2005)

Abstract. Dental implants are established alternatives for replacing missing teeth. Tooth loss for different reasons may lead to alveolar resorption. Shortage of bone can prevent proper positioning of dental implants according to prosthetic needs and treatment planning, unless the volume of hard and soft tissues is increased before implantation. In the esthetic area it is essential not only to achieve well-anchored implants but also sufficient soft and hard tissue in order to obtain natural looking result. This article will present several treatment modalities to augment the soft and hard tissues in order to obtain proper insertion of implants according to prosthetic needs and patient satisfaction. (Keio J Med 54 (4): 172–178, December 2005)

Key words: dental implants, ridge augmentation, surgical techniques, prosthetic guidance

Introduction

Implantology has undergone a number of phases. The developing phase was the period during which we determined whether implants could be placed successfully with achievement of osseointegration. The prosthetic phase represented the development of prosthetic components and techniques that would afford the clinician the ability to place esthetic restorations. Today we realize that for a completely functional and esthetic restoration a complete hard and soft tissue harmony has to be achieved before or during implant placement.

Augmentation of the resorbed alveolar crest, for example, can be achieved with soft and hard tissue onlays, bone grafts, membrane techniques, bone distraction and bone splitting, maxillary sinus floor elevation and bone grafting. Bone grafting and guided bone regeneration can increase the width and, to some extent, also the height of the alveolar bone.^{1,2} Lateral widening, but not vertical augmentation, is possible with a crestal split technique.^{3,4} All of these treatments are very technique-sensitive and have clear indication and contra-indication.

Alveolar Bone Resorption After Tooth Loss

Alveolar bone is a specialized part of mandibular and maxillary bone that forms the primary support for teeth. It is composed of bundles of bone, which is built up in layers in a parallel orientation to the coronal-apical direction of the tooth. The anterior maxillary bone is less dense than mandibular bone but more dense than maxillary posterior bone.⁵ Alveolar ridge defects and deformities can be the results of trauma, periodontal disease, surgical treatment or congenital maldevelopment. Resorption after tooth loss has been shown to follow a certain pattern: the labial site of alveolar crest is primarily resorbed, which first reduces its width and later the height.^{6,7} Alveolar bone is resorbed after tooth extraction or avulsion most rapidly during the first years. Extraction of anterior maxillary teeth is associated with a progressive loss of bone mainly from the labial side.⁷ The loss is estimated to be 40–60% during the first 3 years and decreases to 0.25–0.5% annual loss thereafter.⁸ The cause for resorption of alveolar bone has been assumed to be due to disuse atrophy, decreased blood supply, localized inflamma-

tion or prosthesis pressure.⁸ In order to preserve the form of alveolar crest after tooth loss, some root replicates have been introduced. These are made of e.g. PLA⁹ or bioglass¹⁰ and are able to preserve the crestal width and height but may impair later implantation due to incomplete resorption. Also, autogenous grafts and/or allografts^{11,12} and non-resorbable^{13,14} or resorbable membranes¹⁵ have been used to fill the bone defects and to prevent resorption after tooth loss. Soft tissue augmentation has been achieved with sub-epithelial connective tissue grafts, which preserve gingival color and tissue characteristics.^{16,17} Allogenic grafts and various techniques have also been used for esthetic reasons to maintain the bone and soft tissue level underneath the pontic area in fixed bridges¹⁸ and in improving appearance before prosthetic treatment in localized alveolar ridge defects.¹⁹

Augmentation with Bone Grafts

Autogenous bone is still considered the golden standard in the bone regeneration procedures (Figs. 1.1 to 1.3).²⁰ Studies have shown that autogenous cancellous bone produces successful and predictable results.²⁰ Autogenous bone grafts may act mostly as scaffolds and are thus more osteoconductive than osteoinductive even though osteogenic activity may have remained in the spongy part of the graft.²¹ The disadvantages of autogenous grafts are the need for a second surgical site and its associated morbidity.²² Autogenous grafts can be taken, in fact, in lower volume from the maxillo-facial area or in greater volume from distant sites such as iliac crest, tibia, fibula and even scapula. Intra-oral bone grafting is generally sufficient in treating narrow maxillary alveolar crest. It has been shown that bone grafts taken from the jaws resorb more slowly than other grafts.^{23,24} This might be due to the origin of jawbones, which is membranous while other long bones mainly are endochondral.²³ Membranous bone has been shown to form vascularization of the graft more rapidly than does endochondral bone graft.²⁵ Autogenous bone grafts are either cortical blocks, cortico-cancellous blocks, bone chips or compressed cancellous bone cakes. The amount of bone needed can be predetermined using a surgical template to illustrate the amount of bone needed for implant placement. Suitable intra-oral donor sites are symphysis, maxillary tuberosity, mandibular retromolar area, and zygoma. The bone slurry produced during preparation of implant bed can be harvested using suction-connected bone collector.^{26–28} Contamination with oral bacteria is possible during harvesting procedure but this risk is decreased if harvesting is performed as aseptic as possible.²⁸

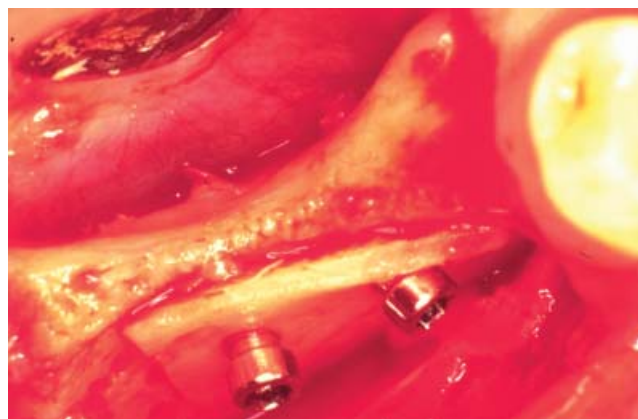


Fig. 1.1 Autogenous block in place form retro-molar area.

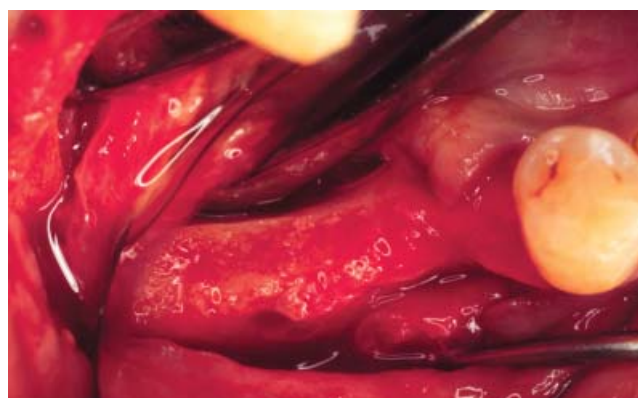

Fig. 1.2 Healing 6 month after grafting. Ridge dimension is now 5 to 6 mm.

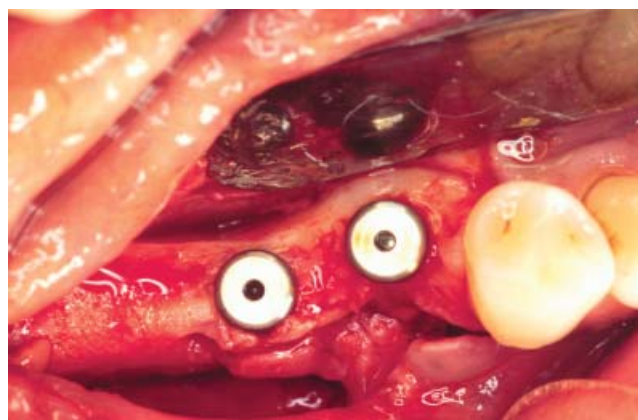

Fig. 1.3 Implant of 4.1 mm of diameter after placement.

Figs. 1.1 to 1.3 Autologous bone harvesting from intra-oral site for horizontal ridge augmentation before implant placement.

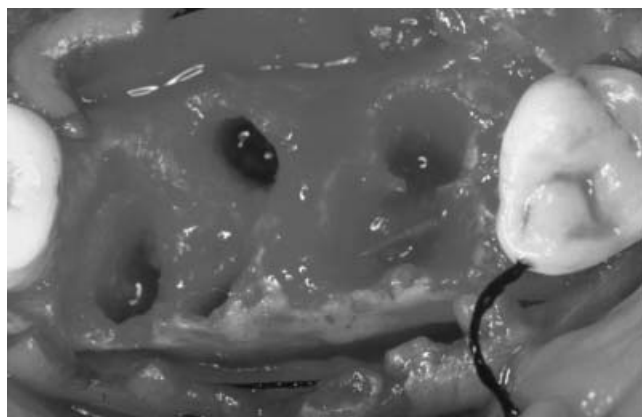


Fig. 2.1 Extraction socket. Reproduced by permission of Quintessence Publishing Co, Inc.

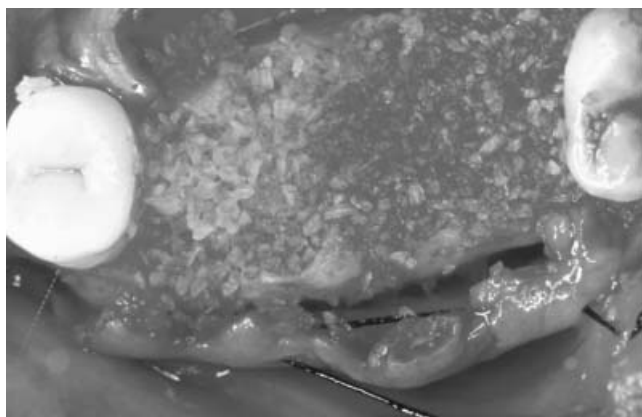


Fig. 2.2 Socket filled with DFDBA. Reproduced by permission of Quintessence Publishing Co, Inc.

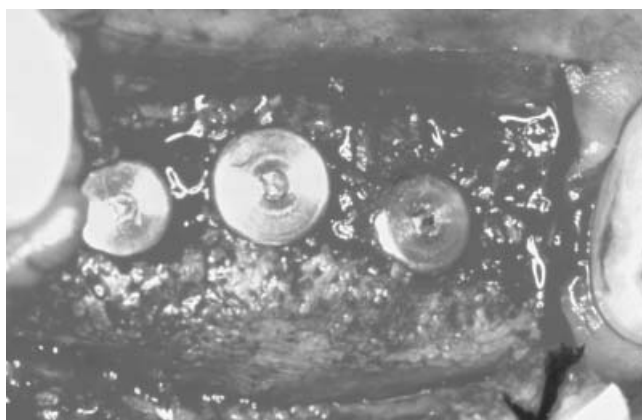

Fig. 2.3 4 months later after implant placement.

Figs. 2.1 to 2.3 Allogeneic bone graft (DFDBA) before implant placement.

Augmentation with Allogenic, Xenogenic or Alloplastic Graft Materials

Allogenic bone material has been extensively used in bone regeneration (Figs. 2.1 to 2.3). Although some doubts have been raised on its biological effects¹² allogenic material may represent a valid alternative to autologous bone graft.^{13,14} Extensive research has been focused on the development of bone substitutes. Many of these products are based on minerals, which are found in bone.²⁶ *Hydroxyl apatite* (HA) is the major bone mineral. It can be also manufactured industrially. HA is non-resorbable while other coral-derived materials are gradually resorbed.^{28,29} *Coral granules* obtained from natural coral skeletons will be completely resorbed and replaced by host bone²⁷ and have been used in bone augmentation procedures.²⁸ Allogenic and xenogenic bone products might be abandoned in the future due to the risk of transmitting diseases. Allogenic, xenogenic and alloplastic materials can be mixed with bone chips and thus decrease the amount of bone graft needed, which in this case can be harvested from intra-oral sites.²⁶

Guided Bone Regeneration

Guided Bone Regeneration (GBR) is a technique in which bone growth is enhanced by maintaining the space and preventing soft tissue in growth into the area utilizing either a resorbable or non-resorbable barrier membrane. GBR may be performed in conjunction with the placement of the implants or during a surgical intervention prior to implant placement. The staged approach is primarily chosen in situations with large bone defects or in esthetic situation, to allow positioning of the implants in the prosthetically desired position. Hence, the alveolar ridge is augmented in a first surgical intervention. After the appropriate time for healing, the implants are then placed into a site of sufficient bone volume (Figs. 3.1, 3.2). Although autologous bone would be normally the material of choice, in a recent clinical study also a de-proteinized bovine bone mineral was applied in conjunction with a bioresorbable collagen membrane.³¹ Metallic membranes³² or membranes supported by titanium frame³³⁻³⁵ have been tested. Acellular matrix has been used as a barrier membrane with demineralized freeze-dried bone allograft.³⁶ Membranes in general are a controversial issue in implantology and their use is at least very technique sensitive.³⁷ Non-resorbable membranes need a second operation for their removal and resorbable membranes can enhance inflammation.³⁸ Intact periosteum or split palatal gingival flaps are regarded by some authors as natural membranes.³⁹ Still, however, good results with augmentation proce-

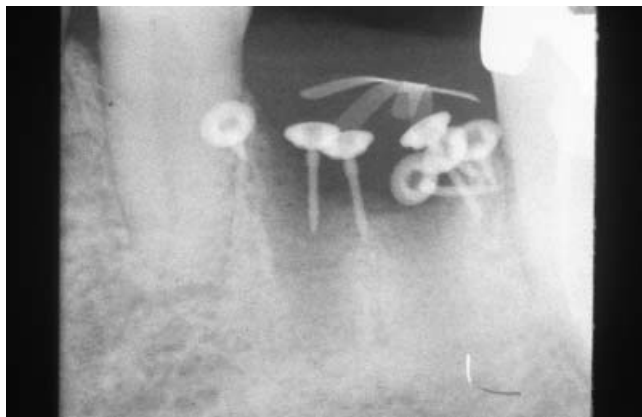


Fig. 3.1 Radiograph of same defect after GBR. Note Titanium Membrane and pins.

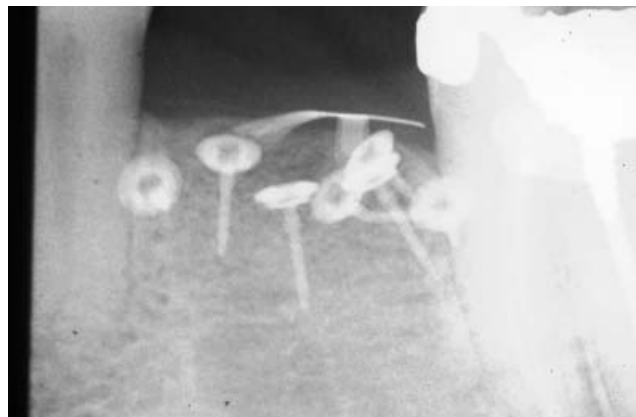

Fig. 3.2 Radiograph after 9 months. Note complete resolution of vertical bone defect.

Figs. 3.1 to 3.2 GBR with e-PTFE membrane. In this case Vertical Augmentation with Titanium reinforced membrane and pins.

dures using membranes have been presented.^{34,35,40-42} Vertical increase of a narrow alveolar crest has been shown to be possible with membranes.³⁴ Membranes are often accompanied with bone grafts beneath them.⁴³ Also, here autogenous bone chips are superior to demineralized allogenic grafts.

Bone Expansion and Split Crest Techniques

Alveolar reconstruction or alveolar widening with osteotomes and chisels produces a greenstick fracture leaving the remaining periosteum attached to the bone. This periosteally pedicled buccal cortex is repositioned and a new implant bed is created without even drilling. The major benefit of crestal widening is that the thin alveolar bone can be utilized for implantation without grafting and the implants placed simultaneously with the bone expansion procedure. One of the problems is generally to assure precise positioning of implants according to prosthetic needs. Since the expansion is achieved by transposition of the buccal plate even more buccally, the implants may have a tendency to be inclined too much in the same direction. Grafting between the fractured cortical lamellae is better integrated and opening of marrow space improves vascularization and healing.⁸ The direction of forces by chisels should be aimed palatally to decrease the damage exerted on the fragile buccal plate. The bone can be flexed to some extent due to its elasticity.⁴ Bone compression is also achieved as well as an increase in the density of trabeculosity in the adjacent site.⁴⁵ The resulting gap can be covered by non-resorbable membrane^{46,8} and filled with allogenic material.⁸ Interpositional autogenous bone grafts have been used to improve bony healing in the gap.⁵ Membranes do not

necessarily improve the prognosis.⁴⁷ Lamellar cortical splitting can be initiated with a diamond disc or burs and finalized with osteotomes.¹⁹ Implants inserted in alveolar bone in which the width has been increased by means of lateral widening have been shown to give success rate between 86 and 97%.^{19,47} This should be regarded as a very acceptable result and is comparable with implantation without bone augmentation.

Sinus Floor Augmentation Techniques

The sinus floor augmentation technique has been extensively utilized in the last 20 years to successfully increase the dimensions of the posterior maxilla for implant placement.⁴⁸ This technique is based on the elevation of the Schneiderian membrane from the floor of the maxillary sinus and the introduction of a bone graft or a bone substitute (Figs. 4.1 and 4.2). This procedure is technically demanding and involves many factors that might affect implant survival such as the type of graft used for augmentation, the surgical technique and the type of implants.⁴⁹ The osteotome technique was introduced to increase primary stability of dental implants in the posterior maxilla.⁵⁰⁻⁵² It is a procedure that has been well established in clinical routine. With implant shaped instruments the trabecular bone is compressed laterally. Moreover, the alveolar ridge can be expanded and the sinus floor can be elevated through a crestal approach.⁵¹⁻⁵³

Vertical Bone Defects

The indications for vertical ridge augmentation include situations where the remaining bone height is too small for proper anchorage of oral implants; unfavor-

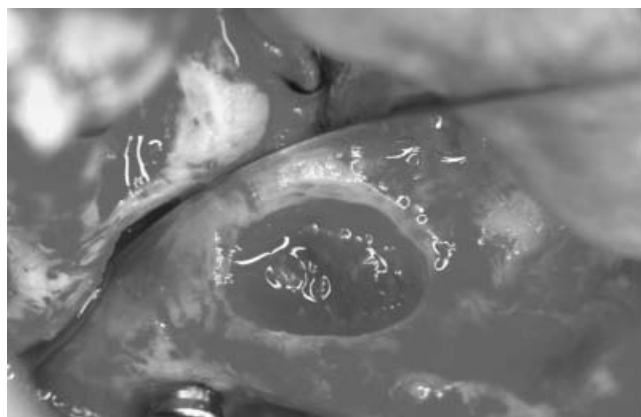


Fig. 4.1 View of buccal window.

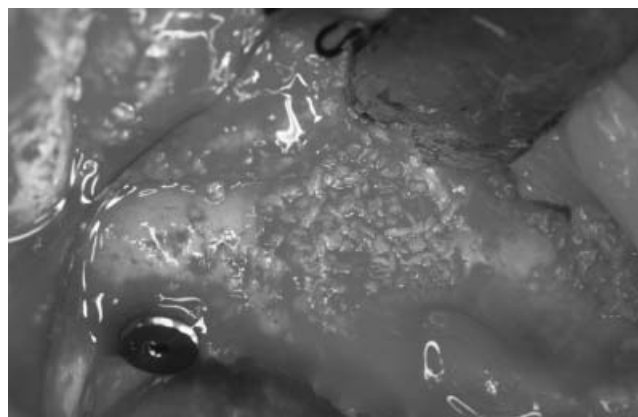


Fig. 4.2 Same view after grafting procedure is completed.

Figs. 4.1 and 4.2 Sinus lift procedure with buccal window approach.

able crown to implant ratios and unfavorable esthetic outcomes will result from the lack of remaining hard and soft tissues (Figs. 2.1 to 2.3). Data from animal experiments have clearly demonstrated that growth of bone above the external borders of the skeleton was possible using GBR.^{54–60} In the first clinical study on vertical ridge augmentation in humans, a titanium-reinforced ePTFE membrane was used to cover implants that were allowed to protrude up to 7 mm above the crest.⁶¹ The results after 9 months of submerged healing showed bone formation reaching up to 4 mm above the previous border of the alveolar crest. The remainder of the space between the newly formed bone and the membrane was occupied by non-mineralized tissue. Within the area of the newly formed bone, osseointegration of the implants had occurred as demonstrated by histologic analysis of experimentally retrieved test implants. In another study, six patients were treated with titanium-reinforced membranes and autogenic bone collected in a suction filter.⁶² Twelve months following membrane placement, an average gain of 5 mm of vertical bone height was measured, reaching up to a maximum of 7 mm.

Soft Tissues Augmentation

Historically, soft tissue management and augmentation has been described to enhance esthetic of fixed bridge.^{63–65} Many techniques of soft tissue augmentation have been used longer before the implants were routinely used in the dental offices. These procedures are extremely technique sensitive and present a variable success rate.^{63–65} Today these techniques are utilized in conjunction with hard tissue augmentation procedures in order to obtain a more predictable success rate and to optimize esthetic and functional results.^{17,19}

Conclusions

To maximize functional and esthetic results, implants should be placed accordingly to prosthetic needs and design. Due to bone resorption after extraction, ideal placement of implants would be often impossible without prior hard and soft tissue augmentation. Several techniques are available nowadays. Advantages and disadvantages of these techniques are presented. Solution of each case requires customization and often combination of these techniques. Thus a deep knowledge of these techniques will allow the surgeon to properly select the right combination for prosthetic needs and especially for the esthetic and function of patients.

References

1. Simion M, Baldoni M, Zaffe D: Jawbone enlargement using immediate implant placement associated with a split-crest technique and guided tissue regeneration. *Int J Periodontics Restorative Dent* 1992; 12: 462–473
2. Simion M, Jovanovic SA, Trisi P, Scarano A, Piattelli A: Vertical ridge augmentation around dental implants using a membrane technique and autogenous bone or allografts in humans. *Int J Periodontics Restorative Dent* 1998; 18: 8–23
3. Lustmann J, Lewinstein I: Interpositional bone grafting technique to widen narrow maxillary ridge. *Int J Oral Maxillofac Implants* 1995; 10: 568–577
4. de Wijs FL, Cune MS: Immediate labial contour restoration for improved esthetics: a radiographic study on bone splitting in anterior single-tooth replacement. *Int J Oral Maxillofac Implants* 1997; 12: 686–696
5. Truhlar RS, Orenstein IH, Morris HF, Ochi S: Distribution of bone quality in patients receiving endosseous dental implants. *J Oral Maxillofac Surg* 1997; 55: 38–45
6. Drago CJ: Rates of osseointegration of dental implants with regard to anatomical location. *J Prosthodont* 1992; 1: 29–31

7. Cawood JI, Howell RA: A classification of the edentulous jaws. *Int J Oral Maxillofac Surg* 1988; 17: 232–236
8. Engelke WG, Diederichs CG, Jacobs HG, Deckwer I: Alveolar reconstruction with splitting osteotomy and microfixation of implants. *Int J Oral Maxillofac Implants* 1997; 12: 310–318
9. Suhonen JT, Meyer BJ: Polylactic acid (PLA) root replica in ridge maintenance after loss of a vertically fractured incisor. *Endod Dent Traumatol* 1996; 12: 155–160
10. Yilmaz S, Efeoglu E, Kilic AR: Alveolar ridge reconstruction and/or preservation using root form bioglass cones. *J Clin Periodontol* 1998; 25: 832–839
11. Wiesen M, Kitzis R: Preservation of the alveolar ridge at implant sites. *Periodontol Clin Investig* 1998; 20: 17–20
12. Becker W, Becker BE, Caffesse R: A comparison of demineralized freeze-dried bone and autologous bone to induce bone formation in human extraction sockets. *J Periodontol* 1994; 65: 1128–1133
13. Brugnami F, Then PR, Moroi H, Leone CW: Histologic evaluation of human extraction sockets treated with demineralized freeze-dried bone allograft (DFDBA) and cell occlusive membrane. *J Periodontol* 1996; 67: 821–825
14. Brugnami F, Then PR, Moroi H, Kabani S, Leone CW: GBR in human extraction sockets and ridge defects prior to implant placement: clinical results and histologic evidence of osteoblastic and osteoclastic activities in DFDBA. *Int J Periodontics Restorative Dent* 1999; 19: 259–267
15. Lekholm U, Zarb GA: Patient selection and preparation. In: Branemark PI, Zarb GA, Albrektsson T, editors. *Tissue integrated prostheses. Osseointegration in clinical dentistry*. Chicago: Quintessence; 1985
16. Breault LG, Shakespeare RC, Fowler EB: Enhanced fixed prosthetics with a connective tissue ridge augmentation. *Gen Dent* 1999; 47: 618–622
17. Adriaenssens P, Hermans M, Ingber A, Prestipino V, Daelemans P, Malevez C: Palatal sliding strip flap: soft tissue management to restore maxillary anterior esthetics at stage 2 surgery: a clinical report. *Int J Oral Maxillofac Implants* 1999; 14: 30–36
18. Fugazzotto PA, De Paoli S: Maintenance of regenerated bone beneath pontics: preliminary clinical report of 43 sites. *Int J Oral Maxillofac Implants* 1999; 14: 392–397
19. Studer S, Naef R, Scharer P: Adjustment of localized alveolar ridge defects by soft tissue transplantation to improve mucogingival esthetics: a proposal for clinical classification and an evaluation of procedures. *Quintessence Int* 1997; 28: 785–805
20. Marx RE: Clinical application of bone biology to mandibular and maxillary reconstruction. *Clin Plast Surg* 1994; 21: 377–392
21. Salonen MA, Oikarinen KS, Raustia AM, Knuutila M, Virtanen KK: Clinical and radiologic assessment of possibilities for endosseous implants and osseointegrated prostheses in 55-year-old edentulous subjects. *Acta Odontol Scand* 1994; 52: 25–32
22. Caminiti MF, Sandor GK, Carmichael RP: Quantification of bone harvested from the iliac crest using a power-driven trephine. *J Oral Maxillofac Surg* 1999; 57: 801–805
23. Smith JD, Abramson M: Membranous vs endochondrial bone autografts. *Arch Otolaryngol* 1974; 99: 203–205
24. Kusiak JF, Zins JE, Whitaker LA: The early revascularization of membranous bone. *Plast Reconstr Surg* 1985; 76: 510–516
25. Oikarinen K, Kainulainen V, Kainulainen T: A method of harvesting corticocancellous bone chips for reconstructive maxillofacial surgery. *Int J Oral Maxillofac Surg* 1997; 26: 103–105
26. Jensen J, Sindet-Pedersen S: Autogenous mandibular bone grafts and osseointegrated implants for reconstruction of the severely atrophied maxilla: a preliminary report. *J Oral Maxillofac Surg* 1991; 49: 1277–1287
27. Young MP, Carter DH, Worthington H, Korachi M, Drucker DB: Microbial analysis of bone collected during implant surgery: a clinical and laboratory study. *Clin Oral Implants Res* 2001; 12: 95–103
28. Kainulainen V, Oikarinen K: Comparison of four bone collectors designed for oral and maxillofacial surgery – an in vitro study. *Clin Oral Implants Res* 1998; 9: 327–332
29. Zide MF: Autogenous bone harvest and bone compacting for dental implants. *Compend Contin Educ Dent* 2000; 21: 585–590
30. Buser D, Dula K, Belser U, Hirt HP, Berthold H: Localized ridge augmentation using guided bone regeneration. 1. Surgical procedure in the maxilla. *Int J Periodontics Restorative Dent* 1993; 13: 29–45
31. Zitzmann NU, Scharer P, Marinello CP, Schupbach P, Berglundh T: Alveolar ridge augmentation with Bio-Oss: a histologic study in humans. *Int J Periodontics Restorative Dent* 2001; 21: 288–295
32. Lekovic V, Kenney EB, Weinlaender M, Han T, Klokkevold P, Nedic M, Orsini M: A bone regenerative approach to alveolar ridge maintenance following tooth extraction. Report of 10 cases. *J Periodontol* 1997; 68: 563–570
33. von Arx T, Cochran DL, Hermann JS, Schenk RK, Higginbottom FL, Buser D: Lateral ridge augmentation and implant placement: an experimental study evaluating implant osseointegration in different augmentation materials in the canine mandible. *Int J Oral Maxillofac Implants* 2001; 16: 343–354
34. Lekholm U, Becker W, Dahlin C, Becker B, Donath K, Morrison E: The role of early versus late removal of GTAM membranes on bone formation at oral implants placed into immediate extraction sockets. An experimental study in dogs. *Clin Oral Implants Res* 1993; 4: 121–129
35. Lekovic V, Camargo PM, Klokkevold PR, Weinlaender M, Kenney EB, Dimitrijevic B, Nedic M: Preservation of alveolar bone in extraction sockets using bioabsorbable membranes. *J Periodontol* 1998; 69: 1044–1049
36. Linde A, Hedner E: Recombinant bone morphogenetic protein-2 enhances bone healing, guided by osteopromotive e-PTFE membranes: an experimental study in rats. *Calcif Tissue Int* 1995; 56: 549–553
37. Lorenzoni M, Pertl C, Keil C, Wegscheider WA: Treatment of peri-implant defects with guided bone regeneration: a comparative clinical study with various membranes and bone grafts. *Int J Oral Maxillofac Implants* 1998; 13: 639–646
38. Lorenzoni M, Pertl C, Polansky R, Wegscheider W: Guided bone regeneration with barrier membranes – a clinical and radiographic follow-up study after 24 months. *Clin Oral Implants Res* 1999; 10: 16–23
39. Chung CP, Kim DK, Park YJ, Nam KH, Lee SJ: Biological effects of drug-loaded biodegradable membranes for guided bone regeneration. *J Periodontol* 1997; 32: 172–175
40. Becker W, Becker BE, Polizzi G, Bergstrom C: Autogenous bone grafting of bone defects adjacent to implants placed into immediate extraction sockets in patients: A prospective study. *Int J Oral Maxillofac Implants* 1994; 9: 389–396
41. Brunel G, Brocard D, Duffort JF, Jacquet E, Justum P, Simonet T, Benque E: Bioabsorbable materials for guided bone regeneration prior to implant placement and 7-year follow-up: report of 14 cases. *J Periodontol* 2001; 72: 257–264
42. Lang NP, Bragger U, Hammerle CH, Sutter F: Immediate transmucosal implants using the principle of guided tissue regeneration. I. Rationale, clinical procedures and 30-month results. *Clin Oral Implants Res* 1994; 5: 154–163
43. Lundgren AK, Lundgren D, Sennerby L, Taylor A, Gottlow J, Nyman S: Augmentation of skull bone using a bioresorbable barrier supported by autologous bone grafts. An intra-individual study in the rabbit. *Clin Oral Implants Res* 1997; 8: 90–95
44. Summers RB: A new concept in maxillary implant surgery: the osteotome technique. *Compendium* 1994; 15: 152, 154–156

45. Burchardt H: The biology of bone graft repair. *Clin Orthop Relat Res* 1983; 174: 28–42
46. Ashman A: Postextraction ridge preservation using a synthetic alloplast. *Implant Dent* 2000; 9: 168–176
47. Sethi A, Kaus T: Maxillary ridge expansion with simultaneous implant placement: 5-year results of an ongoing clinical study. *Int J Oral Maxillofac Implants* 2000; 15: 491–499
48. Boyne PJ, James RA: Grafting of the maxillary sinus floor with autogenous marrow and bone. *J Oral Surg* 1980; 38: 613–616
49. Wallace SS, Froum SJ: Effect of maxillary sinus augmentation on the survival of endosseous dental implants. A systematic review. *Ann Periodontol* 2003; 8: 328–343
50. Summers RB: The osteotome technique: Part 2 – The ridge expansion osteotomy (REO) procedure. *Compendium* 1994; 15: 422, 424, 426
51. Summers RB: The osteotome technique: Part 3 – Less invasive methods of elevating the sinus floor. *Compendium* 1994; 15: 698, 700, 702–704
52. Summers RB: The osteotome technique: Part 4 – Future site development. *Compend Contin Educ Dent* 1995; 16: 1080, 1092
53. Summers RB: Sinus floor elevation with osteotomes. *J Esthet Dent* 1998; 10: 164–171
54. Hammerle CH, Olah AJ, Schmid J, Fluckiger L, Gogolewski S, Winkler JR, Lang NP: The biological effect of natural bone mineral on bone neoformation on the rabbit skull. *Clin Oral Implants Res* 1997; 8: 198–207
55. Kostopoulos L, Karring T: Augmentation of the rat mandible using guided tissue regeneration. *Clin Oral Implants Res* 1994; 5: 75–82
56. Kostopoulos L, Karring T, Uraguchi R: Formation of jawbone tuberosities by guided tissue regeneration. An experimental study in the rat. *Clin Oral Implants Res* 1994; 5: 245–253
57. Lundgren AK, Lundgren D, Sennerby L, Taylor A, Gottlow J, Nyman S: Augmentation of skull bone using a bioresorbable barrier supported by autologous bone grafts. An intra-individual study in the rabbit. *Clin Oral Implants Res* 1997; 8: 90–95
58. Lundgren D, Lundgren AK, Sennerby L, Nyman S: Augmentation of intramembraneous bone beyond the skeletal envelope using an occlusive titanium barrier. An experimental study in the rabbit. *Clin Oral Implants Res* 1995; 6: 67–72
59. Schmid J, Hammerle CH, Stich H, Lang NP: Supraplant, a novel implant system based on the principle of guided bone generation. A preliminary study in the rabbit. *Clin Oral Implants Res* 1991; 2: 199–202
60. Schmid J, Hammerle CH, Fluckiger L, Winkler JR, Olah AJ, Gogolewski S, Lang NP: Blood-filled spaces with and without filler materials in guided bone regeneration. A comparative experimental study in the rabbit using bioresorbable membranes. *Clin Oral Implants Res* 1997; 8: 75–81
61. Simion M, Trisi P, Piattelli A: Vertical ridge augmentation using a membrane technique associated with osseointegrated implants. *Int J Periodontics Restorative Dent* 1994; 14: 496–511
62. Tinti C, Parma-Benfenati S, Polizzi G: Vertical ridge augmentation: what is the limit? *Int J Periodontics Restorative Dent* 1996; 16: 220–229
63. Seibert JS: Reconstruction of the partially edentulous ridge: gateway to improved prosthetics and superior aesthetics. *Pract Periodontics Aesthet Dent* 1993; 5: 47–55
64. Seibert JS: Ridge augmentation to enhance esthetics in fixed prosthetic treatment. *Compendium* 1991; 12: 548, 550, 552 passim
65. Kaldahl WB, Tussing GJ, Wentz FM, Walker JA: Achieving an esthetic appearance with a fixed prosthesis by submucosal grafts. *J Am Dent Assoc* 1982; 104: 449–452